

***A
N
I
M
A
L***



***R
E
S
E
A
R
C
H***



Volume 4 Number 1 (2007)

***I
N
T
E
R
N
A
T
I
O
N
A
L***



**An International Journal Publishing Original Research Involving
the Use of Animals and Animal Products**

ISSN: 159-3115

Website: zoo-umn.org

HISTOPATHOLOGICAL CHANGES INDUCED BY STAPHYLOCOCCAL ENTEROTOXIN PRODUCED IN YOGHURT

¹EZURIKE, Oluchi Augusta, ¹EZEONU, Ifeoma Maureen, * ²CHAH, Kennedy Foinkfu and ²SHOYINKA, Shodeinde Vincent

¹Department of Microbiology, University of Nigeria, Nsukka, Enugu State, Nigeria.

²Department of Veterinary Microbiology and Pathology, University of Nigeria, Nsukka, Enugu State, Nigeria.

Corresponding Author: Ezeonu I. M. Department of Microbiology, University of Nigeria, Nsukka, Enugu State, Nigeria. Email: ifyezeonu@yahoo.com Phone: +2348037954649

ABSTRACT

In this study, six Staphylococcus aureus strains isolated from contaminated yoghurt were evaluated for enterotoxigenicity. Two of the strains were enterotoxigenic and caused fluid accumulation in rabbit ileal loops. Fluid aspirated from the loops was bloody and histopathological changes in sections collected from rabbit ileum, inoculated with crude enterotoxin, were characterized by circulatory disturbances, degenerative/ necrotic and inflammatory changes, including hyperaemia, fibrinous exudation and necrosis of villi epithelial cells. These findings showed that although SE are typically associated with vomiting and diarrhoea, which often abate within 24 hours, there was potential for more serious disturbances such as inflammation, tissue damage and toxic shock. Moreover, the production of potent SE by strains isolated from commonly consumed products such as yoghurt emphasizes the need for complete elimination of staphylococcal contaminants from foods in order to protect consumers.

Keywords: *Staphylococcus aureus*, Enterotoxins, Hyperaemia, Histopathological changes, Necrosis of villi

INTRODUCTION

Staphylococcal foodborne intoxication has been reported to be one of the most common bacterial foodborne outbreaks in many countries (Balaban and Rasooly, 2000; Adwan *et al.*, 2005). A survey of sixteen European countries implicated *Staphylococcus aureus* in 1 – 13% of all reported foodborne disease outbreaks and in the United States there were 42 documented outbreaks due to *S. aureus* between 1993 and 1997 (Mead *et al.*, 1999; ECHCPD, 2003). The enterotoxigenicity typically occurs 30 min to 8 h after ingestion of heat-stable staphylococcal enterotoxins (SEs) synthesized in food by enterotoxigenic strains of coagulase-positive staphylococci (CPS), mainly *S. aureus* (Holeckova *et al.*, 2002; Le Loir *et al.*, 2003).

The staphylococcal enterotoxins are a group of pyrogenic, heat-stable exotoxins with molecular weights of 25 to 29 kDa (Holeckova *et al.*, 2002; ECHCPD, 2003; van Gessel *et al.*, 2004). Currently, there are about 14 serotypes of SE described, which are named sequentially by letter (SEA – SEO), in order of discovery (Jarraud *et al.*, 2001; ECHCPD, 2003; Le Loir *et al.*, 2003). There are no established patterns of SEs production in foods. However, studies have shown a predominance of SEB and SEC producing strains in raw milk, particularly from mastitic cows (ECHCPD, 2003; Kuroishi *et al.*, 2003; van Gessel *et al.*, 2004; Adwan *et al.*, 2005). *S. aureus* are ubiquitous in nature, existing in dust, sewage, water, environmental surfaces, humans and animals body surfaces and may contaminate foods through raw materials or handling during the preparation or manufacturing process. Not all strains produce enterotoxin. Growth and enterotoxin production are subject to a number of genetic and

environmental factors. However, once the enterotoxins are produced, they are normally resistant to both heat and digestive enzymes (ECHCPD, 2003; Le Loir *et al.*, 2003).

Exposure to SE has been shown to cause a range of clinical abnormalities from gastrointestinal upset to lethal toxic shock syndrome (TSS) (Ellis *et al.*, 2003; van Gessel *et al.*, 2004).

In this study, six strains of *S. aureus* isolated from contaminated yoghurt products were evaluated for their enterotoxin-producing ability by the ligated rabbit ileal loop assay and histopathological evaluation conducted on the rabbit intestines.

MATERIALS AND METHODS

Isolation and Maintenance of Bacterial Strains:

Six *S. aureus* isolates were recovered from contaminated yoghurt samples during a study evaluating the microbiological quality of various yoghurt products. Colonies were selected following morphological and biochemical characterization of colonies resulting from nutrient agar plates inoculated with various yoghurt samples. The *S. aureus* strains were routinely maintained in Nutrient broth and stocks were maintained on nutrient agar slants at 4°C.

Culture of *S. aureus* for Enterotoxin

Production: Cultures for enterotoxin production were initially prepared using nutrient broth. Ten milliliter aliquots of sterile nutrient broth, in sterile Bijou bottles, were inoculated each with approximately 10⁵ cells per ml and incubated at 37°C for 48 h.

Subsequently, the *S. aureus* strains were cultured in 10 ml of yoghurt, pasteurized by heating to 80°C for 30 min and cultures were incubated as with nutrient broth cultures.

Preparation of Enterotoxin: Following 48 h incubation of the nutrient broth and yoghurt cultures, cell free culture supernatants were collected by centrifugation at 5000 rpm, followed by filtration through 0.22 µm Millex syringe filters. The cell free filtrates were then used as crude toxin preparation.

Assay for Enterotoxin Activity: Assay for enterotoxin was by ligated rabbit ileal loop method (Ike *et al.*, 2005). Briefly, six to nine week old rabbits were starved for 24 h with water supplied *ad libitum*. Each rabbit was anaesthetized with 2 ml of ketamin injection and secured in dorsal recumbency. Following a midline incision, starting from the rectal end, the ileum was divided into segments of 5 cm in length with string ligatures. The crude toxin preparation (0.5 ml) was injected into different segments. Uninoculated broth and sterile saline were injected into some segments to serve as negative controls. The incisions were then sutured and the animals allowed to recover from anaesthesia. After 7 h, the animals were sacrificed and the segments examined for fluid accumulation (dilatation).

For positive loops, the volume of fluid recovered by aspiration was used to determine the dilatation index (DI) estimated as the ratio of volume of fluid to length of ileal segment. A $DI \geq 0.2$ was taken as positive. The test was done in triplicate animals.

Histopathology: Sections of both normal and enterotoxin-inoculated rabbit ileum were fixed by immersing the cut pieces in 10 % formal saline for 24 – 48 h. Following fixation, the tissues were dehydrated in a series of ascending ethanol concentrations (70 %, 80 %, 90 %, 95 %, and absolute), and then embedded in paraffin. Sections were thereafter cut with a microtome at 5-6 µm. Cut tissues were stained with haematoxylin and eosin and examined microscopically. Photomicrographs were taken.

RESULTS AND DISCUSSION

Of six *S. aureus* isolates tested, two isolates were found to be enterotoxigenic. Cell-free culture supernatants (crude toxin preparations) of the *S. aureus* strains caused fluid accumulation when injected into rabbit ileal segments, indicating enterotoxin activity. Dilatation index (DI) values ranged from 0.2 to 0.57. Moreover, there was a dark-reddish colouration of the positive ileal loops (Figure 1) and the aspirated fluid from such segments appeared bloody. Histopathologic changes in sections collected from the rabbit ileum were characterized by circulatory disturbances, degenerative/necrotic, and inflammatory changes. Sections of the intestine collected from untreated (control) rabbits showed mucosae (including glands) and submucosae with

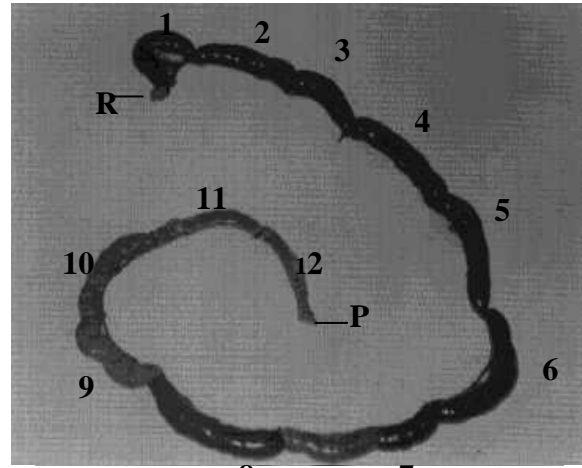


Figure 1: Ligated segments of rabbit ileal loop after injection with crude preparations of staphylococcal enterotoxin (SE) produced under different growth conditions. 1 – 8, SE produced at pH 5; 9 and 10, SE produced at pH 4 – there was change to a brownish colouration but no fluid accumulation; 11, segment inoculated with sterile saline and 12, uninoculated control. R and P, represent the rectal and pyloric ends respectively.

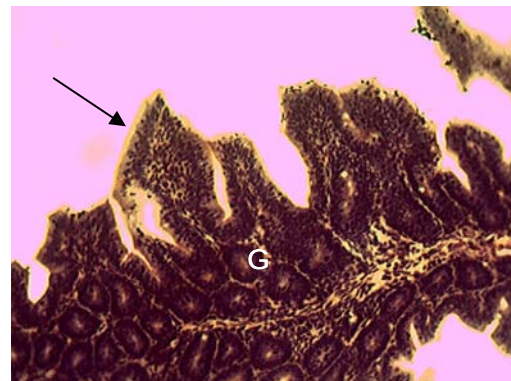


Figure 2: Section of control rabbit ileum showing normal villus (arrow) and intestinal gland (G). H and E stain, x 200.

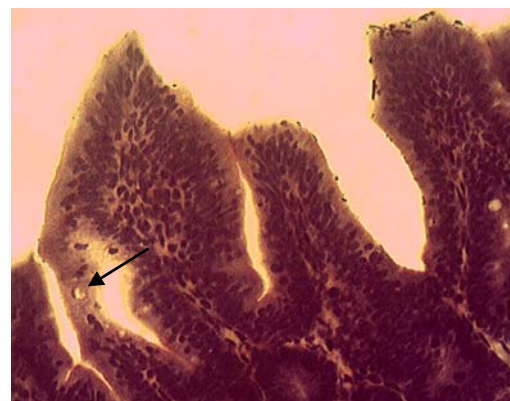


Figure 3: Section of control rabbit ileum showing columnar epithelium lining cells of villi and Goblet cell (arrow). H and E stain, x 400.

normal histomorphology (Figures 2 and 3), while sections from rabbit ileum inoculated with crude toxin preparations showed moderate to severe hyperaemia, with moderate fibrinous exudation onto the intestinal mucosae (Figure 4). In addition, there was distortion of villi epithelium at the tips and necrosis of epithelial lining cells. The intestinal glands were generally normal (Figure 5).

These findings are similar to those reported by other investigators in which various SEs induced varying degrees of inflammatory and degenerative changes. Kuroishi *et al.* (2003), elucidated mechanisms by which SEC induced inflammatory changes in bovine mammary glands. The SEC-inoculated mammary glands exhibited interstitial inflammation, with epithelial cell degeneration and migration of polymorphonuclear neutrophils.

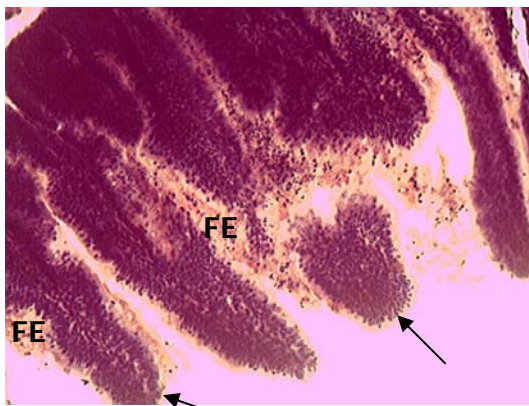


Figure 4: Section of rabbit ileum inoculated with crude staphylococcal enterotoxin, showing fibrinous exudate (FE) on mucosae with degeneration and necrosis of villi epithelial cells (arrow) epithelial cells. H and E stain, x 200.

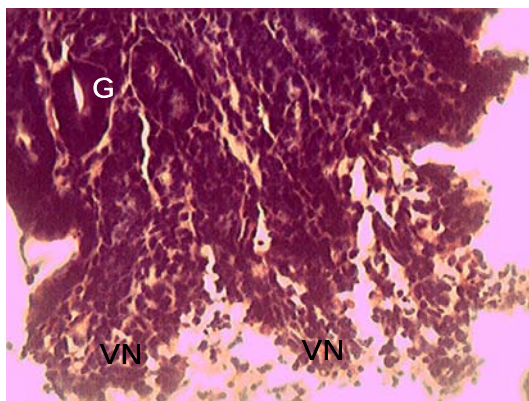


Figure 5: Section of rabbit ileum inoculated with crude staphylococcal enterotoxin, showing necrosis of villi (VN) and normal intestinal gland (G). H and E stain, x 400.

Other studies have shown that exposure to SE can cause a range of clinical abnormalities from gastrointestinal upset to lethal toxic shock syndrome (TSS) and once introduced into host tissues; these toxins have the ability to elicit pathology in different systems (Jett *et al.*, 1990; Greenfield *et al.*, 2002).

Van Gessel *et al.* (2004) working with piglet models demonstrated lethal SEB intoxication. Clinical signs observed in that study included pyrexia, vomiting and diarrhoea within 4 h, followed by terminal hypotension and shock by 96 h. There has even been reported involvement of SEA in a fatal case of endocarditis (Ellis *et al.*, 2003).

The SEs have been reported to act as superantigens (Yokomizo *et al.*, 1995; Johnson *et al.*, 1996; Ferens *et al.*, 1998; Kuroishi *et al.*, 2003; van Gessel *et al.*, 2004) and have the capacity to cause T-cell proliferation with massive inflammatory cytokine release. Much of the lethal effects of SEs have been attributed to this superantigenic activity (Miethke *et al.*, 1992; Jardetzky *et al.*, 1994; Johnson *et al.*, 1996). However, the more common symptoms of intoxication due to SEs remain those of pyrexia, vomiting and diarrhoea, which often abate within 24 h (Jett *et al.*, 1990; van Gessel *et al.*, 2004). Consequently, there may be a tendency by the general population to underestimate the health risks posed by formation of SEs in food. However, the findings in this study, show that vomiting and diarrhoea may be only the least of possible health problems that could result from ingestion of preformed SEs with food, particularly in more sensitive individuals such as the very young and very old.

Although our study describes histological changes in a rabbit model, there is documented evidence that the clinical syndromes in some animal models simulate human enterotoxigenesis (van Gessel *et al.*, 2004). There is, therefore, a need to reassess the importance of preventing the growth of the coagulase-positive staphylococci in foods and their production of enterotoxins.

REFERENCES

- ADWAN, G., ABU-SHANAB, B. and ADWAN, K. (2005). Enterotoxigenic *Staphylococcus aureus* in raw milk in the north of Palestine. *Turkish Journal of Biology*, 29: 229-232.
- BALABAN, N. and RASOOLY, A. (2000). Staphylococcal enterotoxins. *International Journal of Food Microbiology*, 61: 1-10.
- ELLIS, M., SERRELI, A., COLQUE-NAVARRO, P., HEDSTROM, U., CHACKO, A., SIEMKOWICZ, E and MOLLBY, R. (2003). Role of staphylococcal enterotoxin A in a fatal case of endocarditis. *Journal of Medical Microbiology*, 52: 109-112.
- ECHCPD (2003). Staphylococcal enterotoxins in milk products, particularly cheeses. *European Commission Health and Consumer Protection Directorate - Opinion of the Scientific Committee on Veterinary Measures Relating to Public Health*.
- FERENS, W. A., DAVIS, W. C., HAMILTON, M. J., PARK, Y. H., DEOBALD, C. F., FOX, L. and BOHACH, G. (1998). Activation of bovine lymphocyte subpopulations by staphylococcal enterotoxin C. *Infection and Immunity*, 66: 573-580.

- GREENFIELD, R. A., BROWN, B. R., HUTCHINS, J. B., IANDOLO, J. J., JACKSON, R., SLATER, L. N. and BRONZE, M. S. (2002). Microbiological, biological and chemical weapons of warfare and terrorism. *American Journal of Medical Sciences*, 323: 326-340.
- HOLECKOVA, B., HOLODA, E., FOTTA, M., KALINACOVA, V., GONDOL, J. and GROLMUS, J. (2002). Occurrence of enterotoxigenic *Staphylococcus aureus* in food. *Annals of Agriculture and Environmental Medicine*, 9: 179 – 182.
- IKE, S. C., EZEONU, I. M. and MGBOR, N. (2005). Production of *Escherichia coli* heat-labile enterotoxin (LT) in some artificial media and commercially available baby foods. *Bio-Research*, 3: 56-61.
- JARDETZKY, T. S., BROWN, J. H., GORGA, J. C., STERN, L. J., URBAN, R. G., CHI, Y. I., STAUFFACHER, C., STROMINGER, J. L. and WILEY, D. C. (1994). Three-dimensional structure of a human class II histocompatibility molecule complexed with superantigen. *Nature*, 368: 711 - 718.
- JARRAUD, S., PEYRAT, M. A., LIM, A., TRISTAN, A., BES, M., MOUGEL, C., ETIENNE, J., VANDENESCH, F., BONNEVILLE, M. and LINA, G. (2001). *egc*, a highly prevalent operon of enterotoxin gene, forms a putative nursery of superantigens in *Staphylococcus aureus*. *Journal of Immunology*, 166: 669-677.
- JETT, M., BRINKLEY, W., NEILL, R., GEMSKI, P. and HUNT, R. (1990). *Staphylococcus aureus* enterotoxin B challenge of monkeys: correlation of plasma levels of arachidonic acid cascade products with occurrence of illness. *Infection and Immunity*, 58: 3494-3499.
- JOHNSON, H. M., TORRES, B. A. and SOOS, J. M. (1996). Superantigens: structure and relevance to human disease. *Proceedings of the Society for Experimental Medicine*, 212: 99-109.
- KUROISHI, T., KOMINE, K., ASSAI, K., KOBAYASHI, J., WATANABE, K., YAMAGUCHI, T., KAMATA, S. and KUMAGAI, K. (2003). Inflammatory responses of bovine polymorphonuclear neutrophils induced by staphylococcal enterotoxin C via stimulation of mononuclear cells. *Clinical Diagnostic Laboratory Immunology*, 10: 1011-1018.
- LE LOIR, Y., BARON, F. and GAUTIER, M. (2003). *Staphylococcus aureus* and food poisoning. *Genetics and Molecular Research*, 2: 63 – 76.
- MEAD, P. S., SLUTSKER, L., DIETZ, V., MCCRAIG, L. F., BREESE, J. S., SHAPIRO, C., GRIFFINS, P. M. and TAUXE, R. V. (1999). Food-related illness and death in the United States. *Emerging Infectious Diseases*, 5: 605 – 625.
- MIETHKE, T., WAHL, C., HEEG, K., ECHTENACHER, B., KRAMMER, P. and WAGNER, H. (1992). T-cell-mediated lethal toxic shock triggered in mice by the superantigen staphylococcal enterotoxin B: critical role of tumor necrosis factor. *Journal of Experimental Medicine*, 175: 91-98.
- VAN GESSEL, Y. A., MANI, S., BI, S., HAMMAMIEH, R., SHUPP, J. W., DAS, R., COLEMAN, G. D. and JETT, M. (2004). Functional piglet model for the clinical syndrome and postmortem findings induced by staphylococcal enterotoxin B. *Experimental Biology and Medicine*, 229: 1061-1071.
- YOKOMIZO, Y., MORI, Y., SHIMOJO, Y., SHIMIZU, S., SENTUSI, H., KODAMA, M. and IGARASHI, H. (1995). Proliferative response and cytokine production of bovine peripheral blood mononuclear cells induced by the superantigens staphylococcal enterotoxins and toxic shock syndrome toxin-1. *Journal of Veterinary Medical Science*, 57: 299 – 305.

Animal Research International

Volume 4 Number 1, April 2007

CONTENTS	PAGES
1. HISTOPATHOLOGICAL CHANGES INDUCED BY STAPHYLOCOCCAL ENTEROTOXIN PRODUCED IN YOGHURT - EZURIKE, Oluchi Augusta, EZEONU, Ifeoma Maureen, CHAH, Kennedy Foinkfu and SHOYINKA, Shodeinde Vincent	587 – 590
2. IMPACT OF LAMDA CYHALOTHRIN PYRETHROID INSECTICIDE ON THE UPTAKE OF CATIONS AND ANIONS BY THE GILLS OF FRESHWATER CATFISH HYBRID JUVENILE - OTI, Egwu Emmanuel and NWANI, Christopher Didigwu	591 – 596
3. EXOGENOUS TESTOSTERONE STIMULATES GLUCONEOGENESIS IN HYPOPROTEINEMIC ALBINO RAT - NDUKUBA, Patrick Ifeanyichukwu	597 – 600
4. A NEW POLYSACCHARIDE, <i>Detarium microcarpium</i> FROM TRADITIONAL NIGERIAN PLANT FOOD: ITS PHYSIOLOGICAL EFFECTS ON RATS - ONYECHI, Uchenna Agatha ELLIS, Peter and JUDD, Patricia Ann	601 – 607
5. VARIATION IN RELATIVE PALATABILITY OF DIFFERENT FORAGES FED TO RABBITS - OSAKWE, Isaac Ikechukwu and EKWE, Okechukwu Okorie	608 – 610
6. MACROINVERTEBRATE FAUNA OF A NIGERIAN FRESHWATER ECOSYSTEM - ODO Gregory Ejikeme, INYANG Nicholas Matthias, EZENWAJI Henry Maduka Godfrey and NWANI Christopher Didiugwu	611 – 616
7. LENGTH-WEIGHT RELATIONSHIP AND CONDITION FACTOR OF THE ELEPHANT FISH, <i>Mormyrus rume</i> (Valenciennes, 846) IN RIVER OSE, SOUTHWESTERN NIGERIA - ODEDEYI Dominic Olabode, FAGBENRO Oyedapo, BELLO-OLUSOJI, Oluayo and ADEBAYO, Olabode	617 – 620
8. AFZELIA AFRICANA, A NOVEL NON STARCH POLYSACCHARIDE, RAISED FASTING PLASMA CHOLESTEROL AND TRIGLYCERIDE LEVELS OF RAT - ONYECHI Uchenna Agatha, JUDD Patricia Ann and ELLIS Peter Rory	621 – 625
9. DIPTERAN FAUNA OF AN ABATTOIR AND ITS CONTIGUOUS FALLOW PLOT IN A GUINEA SAVANNA ECOSYSTEM - EWUIM, Sylvanus Chima	626 – 629
10. THE USE OF BANANA FLAVOUR ESSENCE, FORMALIN AND ORDINARY WATER IN PITFALL TRAPS IN THE STUDY OF THE DIEL ACTIVITIES OF INSECTS FROM A FALLOW PLOT IN AWKA, NIGERIA - EWUIM Sylvanus Chima and EZEANI Ifeoma	630 – 634
11. LENGTH-WEIGHT RELATIONSHIP AND CONDITION FACTOR OF <i>Clarias gariepinus</i> AND <i>Tilapia zilli</i> IN LAKE ALAU AND MONGUNO HATCHERY, BORNO STATE, NIGERIA – KALU Kalu Mong, UMEHAM Solomon Nnanna and OKEREKE Florence	635 – 638
12. EFFECT OF pH ON THE GROWTH PERFORMANCE OF <i>Heterobranchus bidorsalis</i> (♂) X <i>Clarias gariepinus</i> (♀) HYBRID JUVENILES - IVOKE Njoku, MGBENKA Bernard Obialo and OKEKE Ogochukwu	639 – 642

Published by Department of Zoology, University of Nigeria, Nsukka, Nigeria