



**HEAVY METALS CONCENTRATION IN SELECTED PAINTS IN LAGOS, NIGERIA,
AND THEIR BIOLOGICAL EFFECTS ON *MUS MUSCULUS***

*Doherty, V.F., Adeola, A., Aneyo, I. A., Ovioma, G. O., Duru, M.

Department of Biological Science, Yaba College of Technology, P.M.B. 2011, Yaba, Lagos,
Nigeria.

*Corresponding author: funmilayodoherty@yahoo.co.uk

ABSTRACT

The study was aimed at investigating the concentration of Lead in paints sold in Nigeria and to evaluate the toxic effects in mice exposed to its inhalation. Twenty different paint samples purchased from open markets in Lagos were digested and analyzed. Wooden cages were constructed and painted with the different brands and laboratory mice were kept in the cages. After exposure, blood samples from the mice were collected and analyzed for Lead and histopathology was done. The result indicated the presence of lead ranging from 0.0236 - 97.7814 ppm. Each brand with the highest level of lead was used in painting the mice cages. Three mice were introduced and monitored for about 48 days, the mice were sacrificed and the blood samples were digested and analyzed for lead. Except the control, the result of the blood samples revealed the presence of lead ranging from 0.0551- 0.5127 ppm. The hematology results of the blood samples of the mice for White Blood Cell ranges from 3700 – 11700cmm, Hemoglobin 10 – 15.6g/dl, PCV 32.8 – 50%, Red Blood Cell 7 – 8.58×10¹²/L, Platelet 850000-1292000cmm, Neutrophil 55 – 82%, lymphocytes 10 – 49%, Monocyte 2 – 7%, Eosinophils 1 – 4%, Basophils 0%, Mean Corpuscular Volume 43.6 – 60.2 FI, Mean Corpuscular Hemoglobin 13.2 – 17 pg and Mean Corpuscular Hemoglobin Concentration 28.7 – 30.4g/dl. In the exposed mice, lung tissue showed some reduction in air-filled alveolar spaces, with mild infiltration of interstitium by aggregates of inflammatory cell infiltrates, mild pulmonary inflammation. The investigation revealed that paints sold in Nigeria still contain lead.

Keywords: Hematology, histopathology, inhalation, paints

INTRODUCTION

Paints may have toxic substances with associated degree of impairing the well-being of not only its users but also those who may get in contact with it in one way or the other in the ecosystem.

Lead, though being a toxic element is widely employed in paint because of its ability to serve as colouring agents and additives. Lead is known to be among the toxic elements that bio-accumulates in living organisms when they are exposed to Lead through food, air, and water sources [1]. Lead paint relies on lead compounds such as lead (II) chromate (PbCrO_4 , "chrome yellow"), Lead (II, IV) oxide, (Pb_3O_4 , "red lead"), and lead (II) carbonate (PbCO_3 , "white lead") for its colour [2]. As pigments, they are highly opaque, have high refractive index, resistant to fading, accelerate paints hardening, insoluble in water, moistureless that prevent chemical oxidation which leads to rusting and produces an attractive shiny surface that is durable [2]. The anthropogenic routes by which children get exposed to lead include house dust, toys, confectioneries, soil, and water [3]. When children get exposed to lead through swallowing, breathing or by passive diffusion in the interface between mother and fetus, it will impair the vital functions of a number of body organs, structures, and pathways. They also get exposed to detached fragments of paint from old previously painted walls, windows, doors, artifacts and other surfaces that can result to health hazard [4]. In many developing countries attention is more often given to disaster caused by lead exposures from smelters and battery-recycling operations than from consumer products. In the most recent human disaster episode in Nigeria, over 300 persons died in some local government areas of Zamfara state and Niger state, as a result of poisonous lead gases emanating from mineral mining sites in those area [5]. Many studies have revealed and instituted the effect oral exposure of lead on the renal and digestive systems, but in less developed countries very few studies have been conducted on the possible negative impact the respiratory organs through inhalation of lead used in domestic paints. In Nigeria, there are however no well-documented cases of effect resulting from such exposure. The present study was designed to assess the presence of lead in paints, its effect on some respiratory tissues and hematological parameters using Albino rats.

SAMPLE COLLECTION AND METHODS

Twenty (20) different colours of paint from four different brands were purchased from Mushin, Ojota, Oshodi and Yaba retail outlets in Lagos, Nigeria. In this study, the name of the each brand was assigned a code, as P, F, V, C and D. The code represents the first letter of the brand name.

Exposure to Paint Fumes

Six wooden cages (with spaces that served as ventilation area), were constructed. Five cages were painted with each of the paint brands with the highest lead content and the control was not painted. The experiments were conducted using healthy young mice (4 weeks old). The animals were housed in the cages for about 48 days. Each of the cages except the control was repainted weekly.

Sample and Blood Lead Determination

Samples were prepared according to Standard Operating Procedures for lead in paints [6]. The digestion of the samples was carried out by weighing one gram of each sample into different conical flasks. Trioxonitrate (v) acid, turpentine and deionized water in ratio 1:1:2 was added to each flask. The digested samples were filtered into a sample container and were analyzed using Atomic Absorption Spectroscopy (AAS) (Unicam-969, England) for the presence of lead.

Blood sample collection

Blood samples were collected through ocular puncture for biochemical analyses and the blood samples were transferred to EDTA container, after which they were taken to the laboratory for hematological analysis.

HEMATOLOGICAL ANALYSIS

Determination of Packed Cell Volume (PCV) (%)

This was determined using standard hematological procedure as described by [7]. Well mixed anticoagulated blood (0.5 ml) was aspirated into a capillary tube with one end sealed with plasticine. The tube was spun in a hematocrit centrifuge for 5 minutes and then read off in a PCV reader. The values obtained were recorded as the PCV values.

Determination of Red Blood Cells ($\times 10^{12}/L$)

This was determined using standard hematological procedure as described by [7]. Well mixed anticoagulated blood was diluted 1:20 with 10% Na_2CO_3 solution. The mixture (0.5ml) was loaded into an improved Neubauer counting chamber. Appropriate squares (5 significant squares) were counted and added up to determine the total red cell count.

Determination of Total White Blood Cells Count (mm³)

This was determined using standard hematological procedure as described by [7]. Well mixed anticoagulated blood was diluted 1:20 with Turk solution (2% Glacial acetic acid) in a test tube. This was loaded into an improved Neubauer counting chamber. Appropriate squares (4 significant squares) were counted, added up and divided by 2 to determine the total white cell count.

Determination of Methaemoglobin

It was determined by the method of [8]. Blood was diluted 1:20 fold by volume in 0.25M phosphate buffer to make a 1 in 20 dilution. Exactly 0.2ml of well-mixed anticoagulated blood was dispensed into 3.8ml of phosphate buffer. Triton – x – 100 (0.1 ml) was added and the resulting solution mixed by inversion. The solution was allowed to stand for few minutes for hemolysis to occur. It was then transferred to a cuvette and absorbance read at 634nm against phosphate buffer. This reading was recorded as A1. Few minutes later, crystals of potassium cyanide were added to the solution and the absorbance read again at 634nm. This absorbance was recorded as A2.

Calculation: % Methaemoglobin = $(A1 - A2) \times 100$

Determination of Platelets (x10³/μL)

This was determined using the method described by [9]. The blood sample was diluted 1:20 with 2% ammonium oxalate. The diluted sample was loaded into the Neubauer counting chamber with the aid of a Pasteur pipette. The platelets were counted from appropriate five squares on the chamber under a microscope and summed up to obtain the platelet values.

Histopathological analysis

The mice were anesthetized with chloroform. The lungs were excised and left to fix in 10% formalin for 28 hours. Dehydration was carried out by immersing the fixed tissue in ascending grades of ethanol to remove formalin and water. The tissue was embedded by removing ethanol with xylene to allow the infiltration of paraffin wax. Rotary microtome was used to cut tissue sections into 5-6 microns thick. These sections were stained for 10 minutes with hematoxylin and eosin [10].

RESULTS AND DISCUSSION

The results obtained from the digestion of the paint samples indicated that nineteen out of the twenty paints analyzed contained lead as presented in Table 1. With the exception of colour white in brand V, all the paint samples contained lead. P brand paints had the least average lead content (14.57ppm) while C brand paints had the highest average lead content (41.35ppm). Based on the brands, the average paint lead contents were of the order of C > F >D >V>P. In brand P, paint color red recorded highest lead content (55.18ppm) followed by paint colour orange (1.89ppm) and least by color white (0.36ppm), these values were statistically different at $P < 0.05$. In brand V, paint color yellow recorded highest lead content (25.11ppm) followed by paint colour orange, red and white with values 24.45ppm, 10.17ppm and Not Detected respectively. The lead content of Brand F were 0.167ppm, 3.53ppm, 6.22ppm and 97.78ppm for colour white (lowest), red, yellow and orange (highest) respectively. There was a significant difference in paint colour orange (105.5ppm) and other colours of brand C. With respect to colour, there was a significant difference between the white and other colors (Table 1). Paints color orange had the highest average lead content (51.95 ppm) while those of colour white had the lowest lead content (0.14ppm). With the exception of Paints in brand P and V, colour yellow recorded highest lead content. Based on the colour, the average paint lead contents were of the order of orange > red > yellow >white. The highest concentration of lead (105.5 ppm) was detected in colour Orange manufactured by Company C while the lowest concentration of lead were detected in White paints which is comparable to earlier reports of [11, 12]. This results show that 95% of the paint samples under study do not exceed the standard limit of Pb in paint as stipulated in most developed and developing countries which are 90 $\mu\text{g/g}$ and 600 $\mu\text{g/g}$ [13, 14]. This is in contrast to findings made by [15].

Table 1: Average Lead concentration (ppm) of household paint by color and companies

Paint Brands	White	Orange	Red	Yellow	Aver. Total (ppm)
P	0.36	1.89	55.18	0.86	14.57
V	ND	24.45	10.17	25.11	14.93

F	0.167	97.78	3.53	6.22	26.92
C	0.15	105.5	29.10	30.63	41.35
D	0.02	30.15	8.81	22.11	15.27
Aver. Total	0.14	51.95	21.36	16.99	22.61

(ppm)

Lead concentration in the blood sample of the control and the exposed mice

The result shows the lead concentration in the blood sample of the control and the exposed mice (Figure 1). Blood lead levels were elevated in the exposed mice while lead was not detected in the control. Except in V yellow (0.06ppm) and D orange (0.10ppm) paints, the values of lead in the blood of mice exposed to C orange (0.70 ppm), F orange (0.51ppm) and P red (0.15ppm) paints were in parallel with their magnitude of the lead present in them. This study shows correlated levels of lead in the blood of exposed mice according to the concentration of individual paints. This indicates the high hematotoxicity potential of these paints if exposed to higher concentrations.

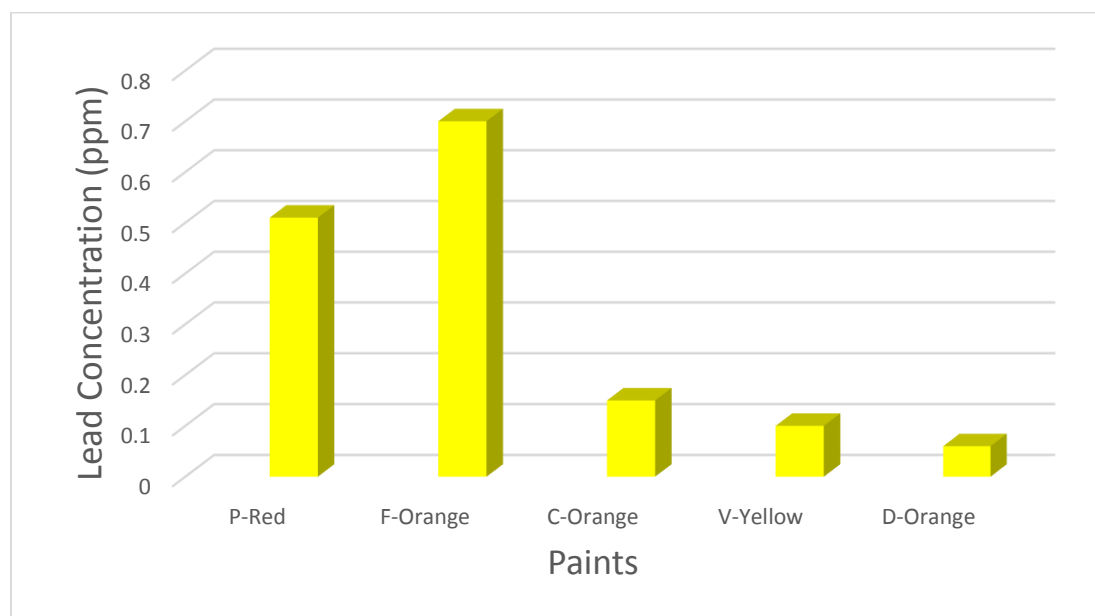


Figure 1: Lead concentration in the blood of exposed mice

Effect on Hematological Parameter

The results obtained from the hematological assessment of the control and exposed animals are presented in Table 2. There were significant difference ($P < 0.05$) in the values of MCV, WBC, HB, MCH, PCV, NEUT, RBC in all experimental groups, when compared with controls and decrease in LYMP and MCHC in the blood samples of the exposed animals. The values obtained indicated that the blood parameters showed no significant difference at ($p < 0.05$) and the results between the experimental groups were within the ranges observed in untreated animals (control) as shown in Table 2. The values for the White Blood Cells (except in paint brand F and P) were higher than that of the control mice. Mice exposed to Paint brand C recorded the highest WBC ($11900 \pm 282.8 \text{ mm}^3$). The neutrophils (NEUT) also recorded higher values than the control animal with paint brand D having highest percentage ($83.00 \pm 1.41\%$). The hemoglobin (HB) showed a non-significant increase ($P < 0.05$) in all the exposed mice percentage where paint F recorded highest value of $15.40 \pm 0.28 \text{ g/dL}$. There was no definite pattern in the percentage of monocytes (MON) in the exposed mice. The data obtained showed non-significant changes in mean corpuscular hemoglobin concentration (MCHC) in both the control and all experimental animals. The data recorded indicated an increase ($P < 0.05$) in eosinophil (EOS) percentage in mice exposed to paints C, D and P. However, no difference ($P < 0.05$) in results was showed in mice exposed to paints V and F when compared with control. Results showed a reduction ($P < 0.05$) of lymphocytes (LYMPH) percentage in experimental mice with lowest value ($11.00 \pm 1.41\%$) in mice exposed to paint D compared to control ($50.00 \pm 1.41\%$). There was an increase ($P < 0.05$) in mean corpuscular volume (MCV) in all the exposed mice where highest value ($59.70 \pm 0.71 \text{ fL}$) in mice exposed to paint P compared to control ($43.85 \pm 0.35 \text{ fl}$). The Erythrocytic Indices such as RBC, PCV, MCV, MCH, and Hb determinations for mice exposed increased and this might be due to low level of Pb in the paints. This trend of results was in conformity with the work of [16] who reported that mean erythrocyte numbers of rats increased with age. The WBC and neutrophil counts of the exposed rats increased significantly. This is in agreement with the findings of [17] the reported that the increase in WBC counts might be due to the systemic status of the animals in relation to its response and adjustment to injurious agents, stress and/or deprivation. The changes in monocyte counts recorded in the study was not found to follow any

definite pattern. However, Lymphocyte showed a significant reduction in exposed mice relative to the control.

Table 2: Average and standard deviation (Mean \pm S.D.) of values of blood parameters of mice exposed to paint

Parameter	Control	C	D	V	F	P
WBC	582z \pm 212.1	11900 \pm 282.8	9850 \pm 495.0	8000 \pm 141.4	1600 \pm 141.4	4900 \pm 1697
RBC	7.48 \pm 0.08	7.89 \pm 0.04	8.21 \pm 0.38	8.81 \pm 0.32	6.75 \pm 0.36	8.05 \pm 0.35
HB	10.65 \pm 0.92	12.50 \pm 0.14	13.80 \pm 0.42	14.50 \pm 0.28	15.40 \pm 0.28	14.80 \pm 0.28
MCV	43.85 \pm 0.35	53.25 \pm 0.78	52.05 \pm 0.50	58.40 \pm 0.42	57.35 \pm 0.64	59.70 \pm 0.71
PLT	957000 \pm 5657	876500 \pm 2121	960000 \pm 2828	1.301e \pm 12728	1.040e \pm 2121	60000 \pm 155563
LYM	50.00 \pm 1.41	12.00 \pm 1.41	11.00 \pm 1.41	37.50 \pm 0.71	41.00 \pm 1.41	11.50 \pm 2.12
MCH	13.65 \pm 0.64	16.10 \pm 0.28	15.65 \pm 0.35	16.45 \pm 0.21	16.70 \pm 0.28	16.65 \pm 0.50
Neut	54.00 \pm 1.41	80.50 \pm 0.71	83.00 \pm 1.41	61.00 \pm 1.41	55.00 \pm 1.41	78.50 \pm 0.71
MON	6.00 \pm 1.41	7.00 \pm 1.41	5.50 \pm 0.71	3.00 \pm 1.41	2.50 \pm 0.71	6.50 \pm 0.71
MCHC	31.05 \pm 0.92	30.00 \pm 0.28	30.95 \pm 0.78	29.10 \pm 0.57	29.70 \pm 0.99	30.25 \pm 0.07
PCV	32.35 \pm 0.64	41.95 \pm 0.50	44.15 \pm 0.35	49.40 \pm 0.85	46.10 \pm 0.99	43.75 \pm 1.06
EOS	1.50 \pm 0.71	2.50 \pm 0.71	3.50 \pm 0.71	1.50 \pm 0.71	1.50 \pm 0.71	3.50 \pm 0.71

*The difference between the value of blood parameters of groups and that of the negative control at 0.05

WBC, White blood cells (mm^3); MCV, mean corpuscular volume (fL); RBC, red blood cells ($\times 10^{12}/\text{L}$); MCH, mean corpuscular hemoglobin (pg); HB, hemoglobin (g/dL); PLT, platelets ($\times 10^3/\mu\text{L}$); LYM, lymphocytes (%); MCHC, mean corpuscular hemoglobin concentration (g/dL); MON, Monocyte (%); PCV, Packed Cell Volume (%); Neut, Neutrophils (%); EOS, Eosinophils (%).

Histology of the lungs of the control and the exposed mice

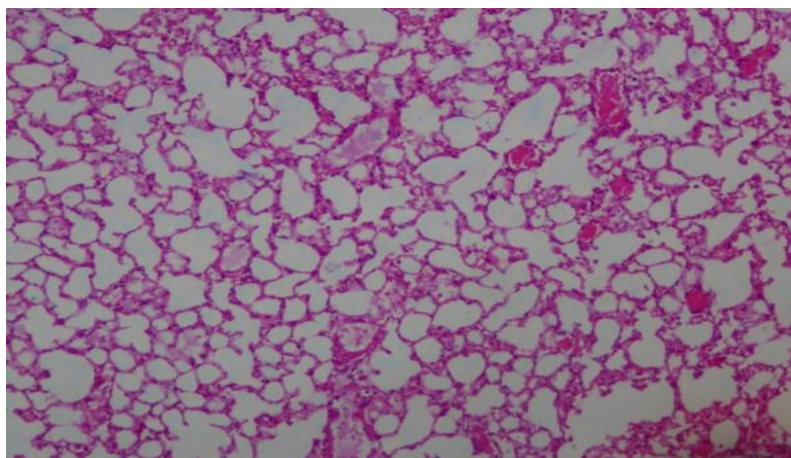


Plate 1: Lung photomicrograph of the control

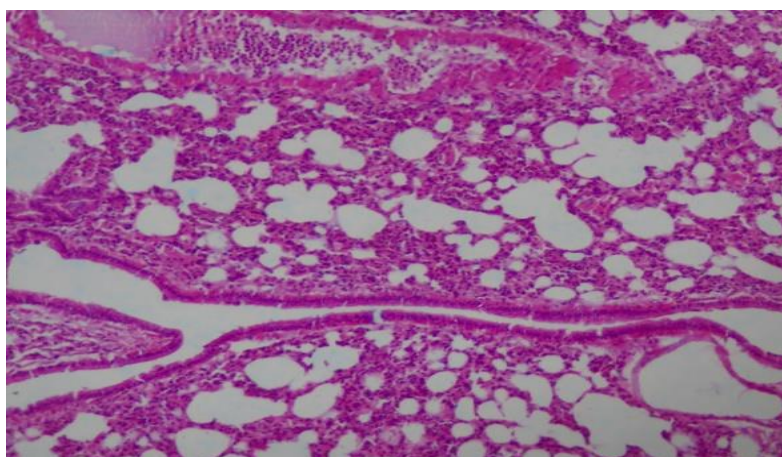


Plate 2: Lung photomicrograph of the exposed mice to paint

The Histology of the lungs photomicrograph of the control (Plate 1) showing air filled alveolar spaces, with minimal alveolar and interstitial inflammatory cell infiltrates, (normal lung). Plate 2 showing Lung photomicrographs of the exposed mice with paint showing some reduction in air-filled alveolar spaces, with mild infiltration of interstitium by aggregates of inflammatory cell infiltrates, mild pulmonary inflammation. The histopathological examination results demonstrated that paint inhalation by the exposed mice with the exception of paint F resulted in reduction in air-filled alveolar spaces, with mild infiltration of interstitium by aggregates of inflammatory cell infiltrates, mild pulmonary inflammation. This is in agreement with the

findings of [18]. Lung is the target organ of lead toxicity [19]. About 90% of lead particles in ambient air that are deposited in the lungs are small enough to be retained. Some studies have suggested that excessive exposure to paint fumes may increase the rate of birth defects, cancers, damage to the central nervous system, miscarriage as well as increasing the risk of childhood asthma and sinusitis. Children are more vulnerable because their lungs are still developing, and breathe frequently than adults making their lungs exposed to a greater dose of air pollution [20]. Lead interferes with the activity of an essential enzyme delta-aminolevulinic acid dehydratase (ALAD), which is important in the biosynthesis of heme, the cofactor found in hemoglobin [21]. It also inhibits the enzyme ferrochelatase, another enzyme involved in the formation of heme that catalyzes the joining of protoporphyrin and Fe^{2+} to form heme [22]. Lead's interference with heme synthesis results in production of zinc protoporphyrin and the development of anaemia, when the cell membranes of red blood cells become more fragile as a result of damage to their membranes [23].

Histology of the Bronchiole of the control and the exposed mice

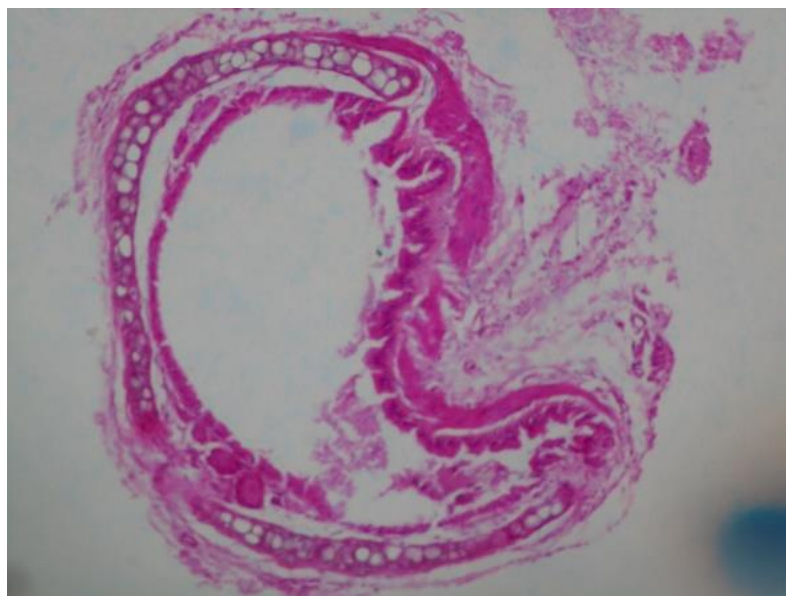


Plate 3: Bronchiole photomicrograph of the Control Mice

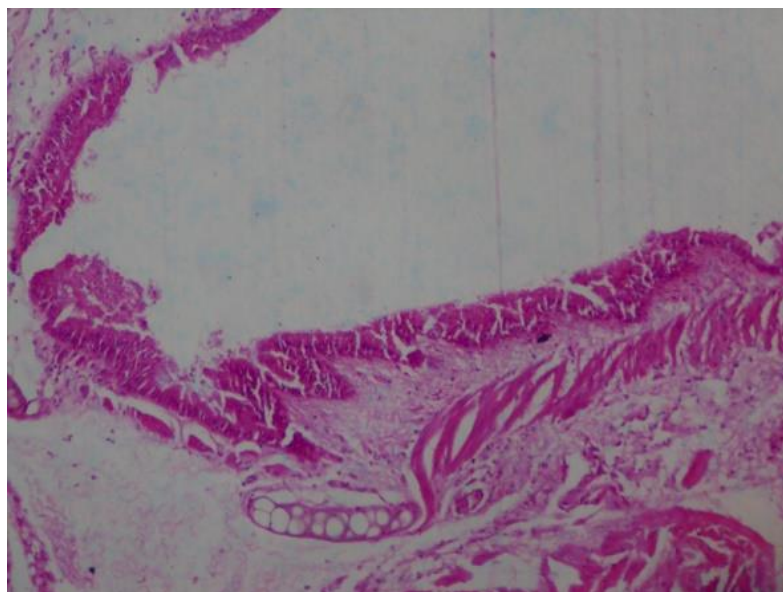


Plate 4: Bronchiole photomicrograph of the exposed mice to Paint

Plates 3 (Control) and 4 reveal the bronchiole photomicrographs of the control and that of exposed mice to paint both showing intact inner lining of tall columnar epithelium surrounded by a muscular wall. The lumen are patent and no abnormalities are seen.

CONCLUSION

This study investigated the presence of Lead in paints, its biological effects on Albino rats, the results revealed that all the studied paints manufactured in Nigeria still possess lead-containing pigment. However, there is need for increased awareness on the effects of these Lead contaminated commercial paints as this study showed effect on the hematological parameters in exposed laboratory rats.

REFERENCES

1. Patra, R. C., Rautray, A. K., & Swarup, D. (2011). Oxidative stress in lead and cadmium toxicity and its amelioration. *Veterinary medicine international*. 2011, 1-9.
2. Völz, H. G., Kischkewitz, J., Woditsch, P., Westerhaus, A., Griebler, W. D., De Liedekerke, M. & Trenczek, G. (2006). Pigments, inorganic. *Ullmann's Encyclopedia of Industrial Chemistry*.

3. Lanphear, B. P., Matte, T. D., Rogers, J., Clickner, R. P., Dietz, B., Bornschein, R. L., ... & Rabinowitz, M. (1998). The contribution of lead-contaminated house dust and residential soil to children's blood lead levels: a pooled analysis of 12 epidemiologic studies. *Environmental research*, 79(1), 51-68.
4. Clark, S., Grote, J., Wilson, J., Succop, P., Chen, M., Galke, W., & McLaine, P. (2004). Occurrence and determinants of increases in blood lead levels in children shortly after lead hazard control activities. *Environmental Research*, 96(2), 196-205.
5. Lo, Y. C., Dooyema, C. A., Neri, A., Durant, J., Jefferies, T., Medina-Marino, A., ... & Samson, M. Y. (2012). Childhood lead poisoning associated with gold ore processing: a village-level investigation—Zamfara State, Nigeria, October–November 2010. *Environmental Health Perspectives*, 120(10), 1450.
6. Clark, C. S., Speranskaya, O., Brosche, S., Gonzalez, H., Solis, D., Kodeih, N., ... & Lind, C. (2015). Total lead concentration in new decorative enamel paints in Lebanon, Paraguay and Russia. *Environmental research*, 138, 432-438.
7. Hussain, Aafreen, Ankur Joshi, Sapna Malviya, and Anil Kharia. "Anti-anemic Activity of Seeds of *Trigonella Foenum-graecum* in Male Albino Rats." *Journal of Pharmaceutical and Biomedical Sciences* 6, no. 11 (2016).
8. Bertrand, A., Cox, C., Foucart, P., & Buret, J. (1982). Determination of serum methemalbumin by second-derivative spectroscopy. *Clinica Chimica Acta*, 123(1-2), 121-126.
9. Cheesbrough, M. (2006). *District laboratory practice in tropical countries*. Cambridge university press.
10. Janovsky, M., Bacciarini, L., Sager, H., Gröne, A., & Gottstein, B. (2002). *Echinococcus multilocularis* in a European beaver from Switzerland. *Journal of Wildlife Diseases*, 38(3), 618-620.
11. Clark, C. S., Rampal, K. G., Thuppil, V., Roda, S. M., Succop, P., Menrath, W. & Adebamowo, C. A. (2009). Lead levels in new enamel household paints from Asia, Africa and South America. *Environmental research*, 109(7), 930-936.

12. Kumar, A., & Gottesfeld, P. (2008). Lead content in household paints in India. *Science of the total environment*, 407(1), 333-337.
13. Ahametun, N. C., Osibanjo, O., Sunday, A. A., & Ogoko, E. C. (2014). Current levels of lead in paint sold in Nigeria. *South Am J Public Health*.
14. Apanpa-Qasim, A. F., Adeyi, A. A., Mudliar, S. N., Raghunathan, K., & Thawale, P. (2016). Examination of lead and cadmium in water-based paints marketed in Nigeria. *Journal of Health and Pollution*, 6(12), 43-49.
15. Adebamowo, E. O., Clark, C. S., Roda, S., Agbede, O. A., Sridhar, M. K., & Adebamowo, C. A. (2007). Lead content of dried films of domestic paints currently sold in Nigeria. *Science of the Total Environment*, 388(1-3), 116-120.
16. Schalm, O. W. (1975). Normal value in blood of laboratory, fur-bearing, and Miscellaneous Zoo and Wild animals. *Veterinary Hematology*, 219-283.
17. Coles, E. H. (1986). Erythrocytes, leukocytes and bone marrow. *Veterinary Clinical Pathology*, 4th. edn. Philadelphia: Saunders, 10-97.
18. Sharma, S., & Singh, B. (2014). Effects of acute and chronic lead exposure on kidney lipid peroxidation and antioxidant enzyme activities in BALB-C mice (*Mus musculus*). *Int. J. Sci. Res*, 3, 1564-1566.
19. El-Nouri, A. A. (2009). The effect of lead on lung histology of albino mice *Mus musculus*. *Rafidain journal of science*, 20(2 E), 29-36.
20. Wax, P. M., & Beuhler, M. B. (2004). Hydrocarbons and volatile substances. *Emergency Medicine: a comprehensive study guide*. 6th ed. NewYork: McGraw Hill.
21. Patrick, L. (2006). Lead Toxicity, a review of the literature. Part I: Exposure, Evaluation, and treatment. *Alternative medicine review*, 11(1).
22. Barbosa Jr, F., Tanus-Santos, J. E., Gerlach, R. F., & Parsons, P. J. (2005). A critical review of biomarkers used for monitoring human exposure to lead: advantages, limitations, and future needs. *Environmental health perspectives*, 113(12), 1669-1674.
23. Erickson, T. B., Ahrens, W. R., Aks, S., Baum, C., & Ling, L. (2005). *Pediatric toxicology: Diagnosis and management of the poisoned child*. McGraw Hill Professional.